

## REVOLUTIONIZING HOPE

### Stereotactic Radiation (SRS/SRT) can be used to treat a wide variety of cancers

#### Head and Neck

- Oral melanoma
- Nasal tumors
- Squamous cell carcinoma
- Plasmacytoma
- Acanthomatous ameloblastoma
- Thyroid carcinoma
- Pituitary tumors
- Ceruminous gland carcinoma
- Salivary gland carcinoma
- Brain tumors (glial and meningioma)

#### Spinal Tumors

- Intradural extramedullary, extradural
- Vertebral body (osteosarcoma, multiple myeloma)

#### Extremity Tumors

- Osteosarcoma
- Mast cell tumors
- Histiocytic sarcoma
- Soft tissue sarcomas
  - Hemangiopericytoma
  - Nerve sheath tumor
  - Fibrosarcoma
  - Infiltrative lipoma

#### Lung and Liver Tumors

- Primary
- Oligometastases

#### Pelvic Canal

- Anal sac adenocarcinoma +/- pelvic lymph nodes
- Prostatic carcinoma/TCC
- Colon

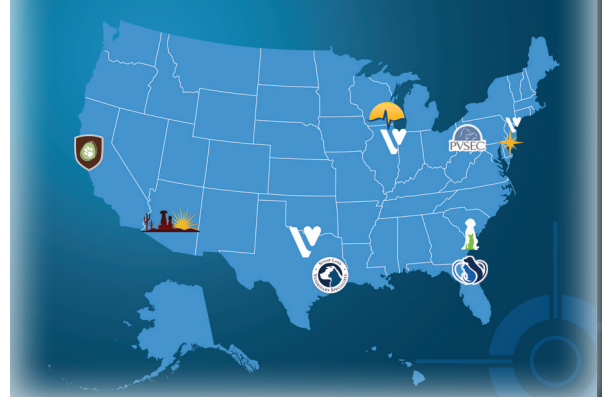Cancer is a terrible diagnosis to have to deliver to a client.

But a new cancer therapy has emerged. **Stereotactic radiation (SRS/SRT)** can be used to treat many cancers, including some previously considered “untreatable.” In only 1-3 treatments, a dose of radiation is delivered with sub-millimeter precision, maximizing impact while minimizing side effects.

PetCure Oncology is providing access to SRS/SRT across the country, offering a targeted, non-surgical cancer care option.

**Cancer is their diagnosis.  
You are their hope.**

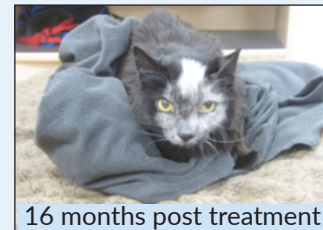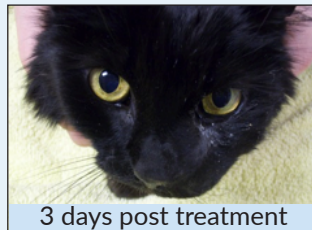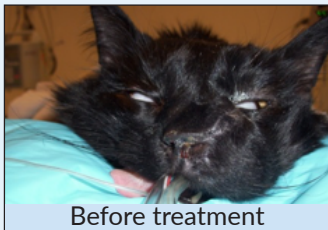#### PetCure-Affiliated Treatment Centers



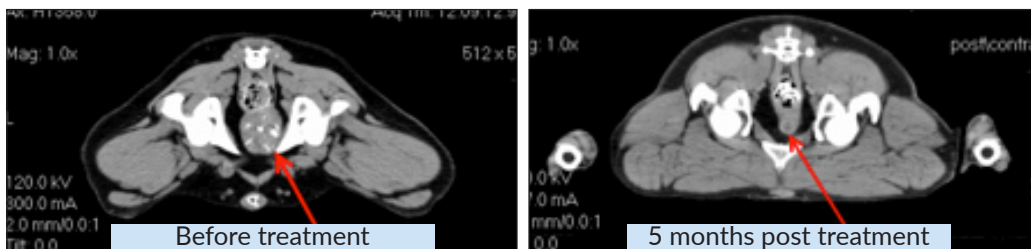
## Treatment that works...

⊕ **Osteosarcoma** – Treatment without amputation. When amputation is simply not an option for your client or their pet, SRS can stop the tumor, extending and enhancing the pet's quality of life.

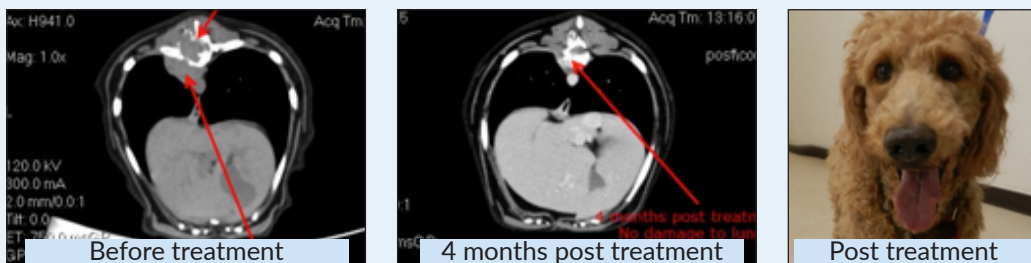⊕ **Melanoma** – Normally, oral melanomas are difficult to treat. Beauty, the 13-year-old cat seen below, proved that SRS has changed the landscape. The precision of the treatment enabled us to shrink the tumor without damaging her eyes. She is pictured below three days post-treatment with no visible radiation burns, and 16 months after treatment with nothing more than some hair discoloration. SRS allowed Beauty to live another two years.



⊕ **Prostate cancer** – This prostatic transitional cell carcinoma used to have a prognosis of 2-3 months. Notice the reduction in size at five months. This dog survived over 18 months with NO side effects from the treatment.



⊕ **Spinal tumor** – Ali had an inoperable spinal tumor. His family was initially told there was nothing that could be done... but SRS gave them another 17 months together.



⊕ **Tonsillar squamous cell** – Jumble was diagnosed with a large tonsillar mass. His owner works in the human medical field. Knowing that the average survival time for this tumor is only six weeks from diagnosis, she turned to SRS to treat him with curative intent. Jumble lived another 27 months and never had a local recurrence of the tumor (he died of pulmonary metastasis).

